

ORIGINAL ARTICLE

Diagnosis of *Toxocara* sp. from Lions by PCR technique

Afkar M. Hadi\*<sup>1</sup> & Haider Malik Al-Zamili<sup>2</sup>

<sup>1</sup>Iraq Natural History Research Center and Museum /University of Baghdad, Baghdad, Iraq.

<sup>2</sup> Al -Zawraa Park Zoo, Amanat Baghdad/Iraq.

\*Corresponding Author Email: [afkar\\_hadi\\_iraq@yahoo.com](mailto:afkar_hadi_iraq@yahoo.com)

ABSTRACT

This study was conducted on Asiatic lions *Panthera leo* (Linnaeus, 1758) kept in Al-Zawraa park in Baghdad city the capital of Iraq. The fecal samples of 28 Asiatic lions (4 male, 7 female and 17 cubs) were collected for three stages pre-treatment, during treatment and post treatment that programmed with anthelmintic therapy (Overmix one tablet per 10 kg) for eight months from March to October 2017. Morphological examination of the eggs and worms was described and delineated as *Toxocara canis* and *Toxocaris leonina* after study of differential characteristic between them. DNA extraction were applied for adult worms by using Organic extraction depending on chemical material. Polymerase chain reaction were performed to confirm the diagnosis of species of *Toxocara* by using specific primers for *T. canis*. The target gene was ITS-2 its number from NCBI was AB110034. PCR technique produce 380bp of fragment of target gene ITS-2 gen confirming *Toxocara canis* in lions.

**Keywords:** Lion, *Toxocara canis*, *T. leonina*, molecular, organic method.

Received 04.07.2018

Revised 28.07.2018

Accepted 26.09.2018

**How to cite this article:**

Afkar M. Hadi and Haider Malik Al-Zamili. Diagnosis of *Toxocara* sp. from Lions by PCR technique. Adv. Biores., Vol 9 [6] November 2018:14-21.

INTRODUCTION

There are scanty in the survey of parasites in the lions in all the world, however few reported for groups of wild animals as Bengal tigers, jaguars, pumas, lynx and lions from various zoological gardens from different part of world from time to time [9]. Opara *et al.*, [10] revealed that lion infected with *Ascaris* sp. 50% in The Zoological Garden, Nekede Owerri, Southeast Nigeria, but they not delineated the species of *Ascaris*. Okulewicz *et al.*, [8] they reviewed the infection of wild animals with *Toxocara canis*, *T. cati* and *Toxocaris leonina*. In Iraq, our country there aren't find any survey about lions except one study of protozoa parasites in the fecal samples of different animals domestic and wild in Al-Zawraa zoo [11]). So, the current study considered the first time in Iraq.

The aims of the current study are: first- determination the infection of *Toxocara* sp. in lions in three stages pre-treatment, during treatment and post treatment that programmed with anthelmintic therapy. Second-classification study between *Toxocara* sp. and *Toxocaris leonina* Third- Molecular study to confirm the species of *Toxocara*.

MATERIALS AND METHODS

This study was conducted during March to October 2017 on Asiatic lions *Panthera leo* (Linnaeus, 1758) kept in Al-Zawraa park in Baghdad city the capital of Iraq.

**Collection of samples**

The fecal samples of 28 Asiatic lions (4 male, 7 female and 17 cubs) were collected for three stages pre-treatment, during treatment and post treatment that programmed with anthelmintic therapy (Albendazole 10mg/ kg + Praziquantel 2mg/kg). The dose is repeated every 10 days during treatment and then returned every three months post treatment

these three stages schedule for eight months from March to October 2017. All the samples were transferred to the workplace Iraq Natural History Research Center and Museum/University of Baghdad.

Flotation method was applied for all fecal samples as Thienpont *et al.*, [13] by using sheather's solution was prepared by Tom [14]. Individual parasites were repeatedly washed in physiological saline, pH 7.3 and put it in alcohol 70% (figure 1). Many of worms (male & female) were put in Formalin Alcohol Azocarmine Lactophenol (FAAL) [1] for morphologic study. Morphological examination of the worms was described according to Bowman [2].

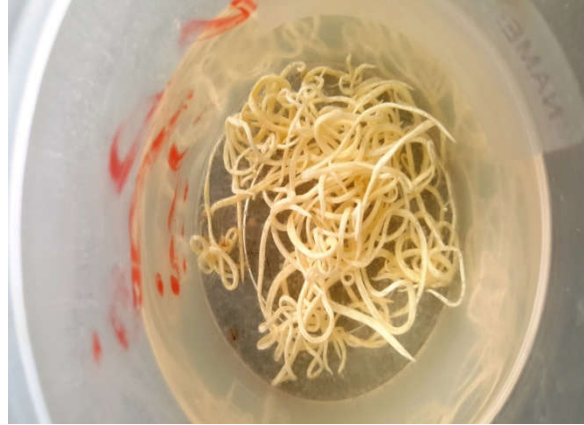

Figure 1: Adult worms of *Toxocarasp*.

#### DNA extraction

About one centimeter tissues of adult worms were sent to the molecular laboratory for DNA extraction and PCR technique. Two methods of DNA extraction were applied, first one by using gSYNC DNA Extraction Kit (Geneaid) for 8 samples. Second one by using Organic extraction depending on chemical material of 5 samples of adult worm tissues.

#### Chemical material

- 1-Stain buffer extraction.
- 2-Proteinase K (10ml/ml).
- 3-Phenol-chloroform isoamyl alcohol
- 4-Saturated ethanol
- 5-70% ethanol.
- 6-TE buffer

#### Genotyping:

Polymerase chain reaction were performed to confirm the diagnosis of species of *Toxocara* by using specific primers for *T. canis*. The target gene was ITS-2 its number from NCBI was AB110034 (Khademvatan *et al.*, 2013), the sequences of these primers have been listed as below:

(F): 5'-AGTATGATGGGCGCGCAAT-3' and (R): 5'-TAGTTTCTTTTCCTCCGCT-3' [4]. Primers from ALPHA Canadian company.

## RESULTS AND DISCUSSION

A total of 28 fecal samples were collected from lions once per week, that mean about 896 samples per eight months. The result of first week was 100% positive for *Toxocara sp.* infection, that encourage to start with treatment programmed antihelminths. This high prevalence of infection can be explained by the favorable climatic conditions, which support prolonged survival of the eggs in the environment; in addition of the feeding management and improper disposal of feces. This result is similar to Khatun *et al* [6] who revealed to Indian Lion was infected with *Toxascaris leonina* 100%, in Rangpur Recreational Garden and Zoo in Bangladesh. However, Virendra *et al.* [16] revealed to *Toxocara sp.* in lions in Nandan Van Zoo, Raipur without delineated the species may be the difficult of diagnosis the species.

The current study recorded two species of Ascarides in Asiatic lions *Panthera leo leo* that was lineated as *Toxocara sp.* and *Toxocaris leonina* by morphological study and then molecular study confirmed the specie of *Toxocara* was *T. canis*. These findings of the presence of two parasites in lions were similar to Okulewicz *et al.*, [9] who suggest that these parasite species do not have genetic barriers preventing them from settlement in different definitive hosts and thus have increased chance of survival.

#### Morphological study

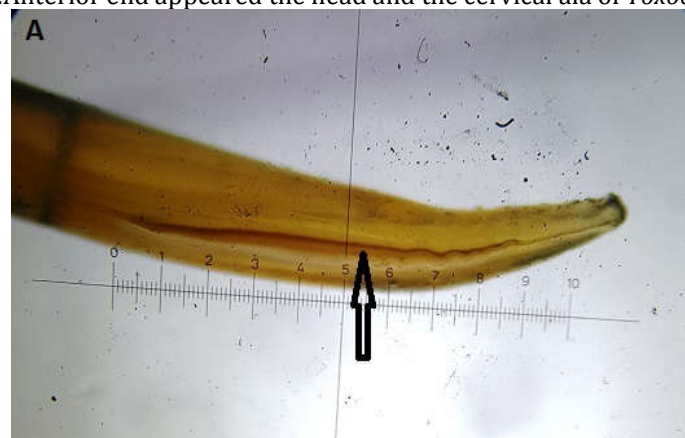Classification of species of Ascarides was lineated as *Toxocara sp.* and *Toxocaris leonina* according to differentiated characteristics like shape of the head, the cervical alae, the esophagus, the tail and the egg, in table 1. Approximately 90 % of eggs measured were of similar size, so the measurements of eggs not benefit in the differentiation of *Toxocara sp.* [15].

**Table.1.**Identification characters between *Toxocara* sp. and *Toxocaris leonina* lion.

organ	<i>Toxocara</i> sp.	<i>Toxocaris leonina</i>
The head	resembles an arrowhead	resembles a spear
The cervical alae	elliptical and broad fig.2	longer and considerably narrower fig.3
The esophagus	It has ventriculus that intercalated between the esophagus and the intestine fig.4	No ventriculus, the esophagus connects to the intestine directly fig.5
The tail	The tail of the male is fingerlike projection fig.6	The tail of the male conical tapers gradually without fingerlike projection fig.7
The egg	Spherical shape , thick, rough, pitted shell, dark brown to black granular contents, un segmented and usually occupying the whole of the shell. Medium sized about 30X30.5 mm. fig.8	Oval, thick,smooth and colorless shell, yellowish brown and granular contents, un segmented and occupying only part of the shell. Medium sized about 40.5 X 40.9 mm.fig.9


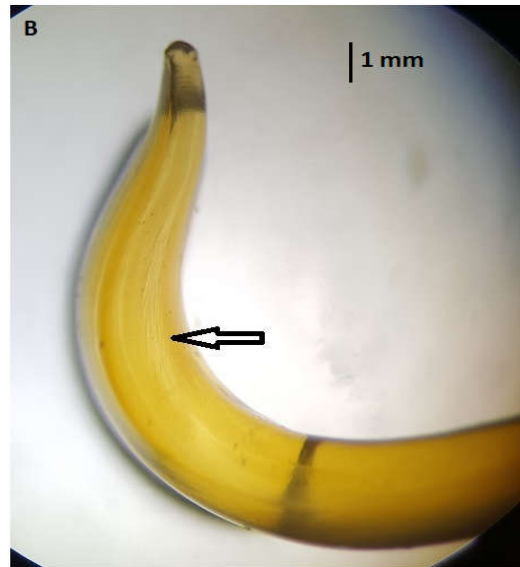
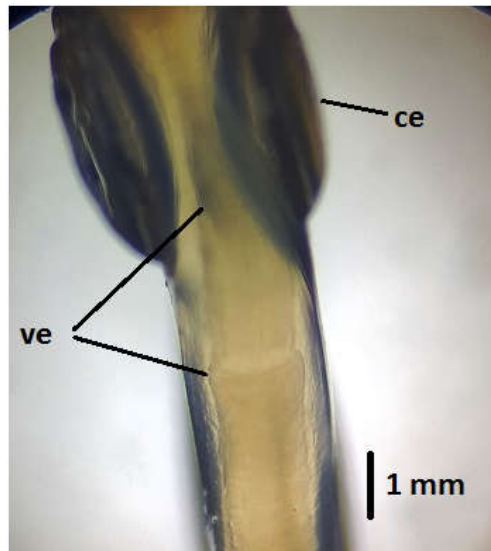


Figure 2:Anterior end appeared the head and the cervical ala of *Toxocara canis*.






**Figure 3:**Anterior end appeared the head and the cervical alae in A. male and B. female of *Toxocaris leonina*.



**Figure 4:***Toxocaracanis* has ventriculus that intercalated between the esophagus and the intestine, ce=cervical alae, ve=ventriculus.



**Figure 5:**The esophagus connects to the intestine directly without a ventriculus in *Toxocaris leonina*.

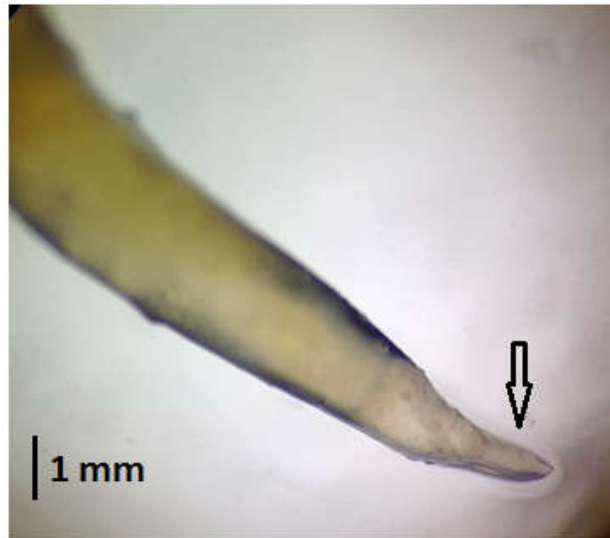

Figure 6: The tail end of the male of *Toxocara canis* has finger like projection.




Figure 7: The tail of the male of *T. leonina* tapers gradually without fingerlike projection.

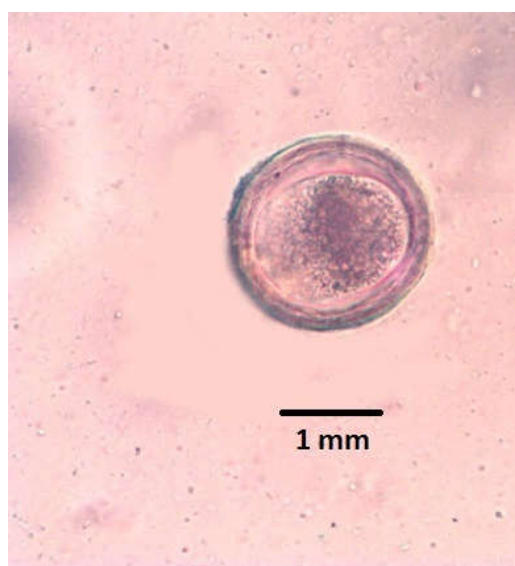

Figure 8: Egg of *Toxocaracanis* in lion.

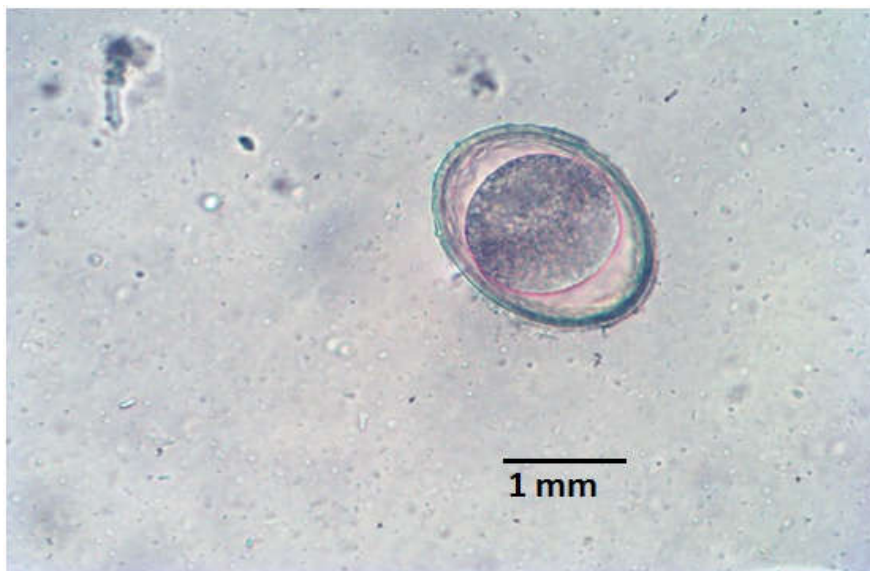

Figure 9: Egg of *Toxocaris leonina* in lion.

### Molecular study

The result of first method of DNA extraction by using gSYNC DNA Extraction Kit (Geneaid) was negative, that contrast with Hadi and Kawan [3]. This result may be due to the lack of validity of the kit.

The result of second one by using Organic extraction depending on chemical material was positive (figure 10) which obtained 100ng a pure DNA that purity was 1.6 for PCR amplification. This finding was similar to Sambrook [12] who revealed to the purity range of DNA was between 1.6 - 2.

The PCR was applied to amplify the targeted fragment which was specified by using specific primers that were designed manually in the *T. canis* specific part of ITS2 Sequences. The result of fragment size amplified was 380 bp in ITS2 gene in figure 11. This result was similar to Khademvatan *et al.*, [5] who revealed that the positive control of *T. cani* consist of 380 bp. However, Moudgil *et al.*, [7] confirmed that Asiatic lions (*Panthera leopersica*) kept at Zoological Park, Chhatbir, Punjab, India were infected only with *Toxocaris leonina*.

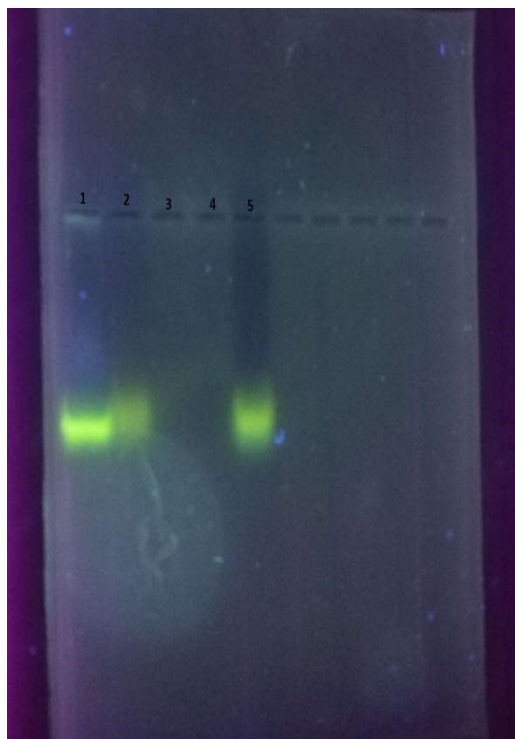


Figure 10: DNA extraction from adult worm of *Toxocara sp.* by Organic method.




Figure 11: PCR technique produce 380bp of fragment of target gene ITS-2 gen confirming *Toxocara canis* in lions.

## CONCLUSION

It may be concluded from the current study that Asiatic lions *Panthera leo* (Linnaeus, 1758) which kept in Al-Zawraa park in Baghdad city/Iraq were infected with *Toxocara canis* and *Toxocaris leonina*. These findings were delineated by morphological and molecular studies.

## ACKNOWLEDGMENTS

We extend our thanks and appreciation to the management of the Al Zawraa Park zoo to facilitate field survey and sample collection.

## REFERENCES

1. Al-Quraishi MA.(2013). Study of histological and physiological effects of *Toxocaracati* larvae infection in experimentally infected white rats. International Journal Current Microbiology Applied Science. 2(8): 49-59.
2. Bowman D D. (2009).Georgis' parasitology for veterinarians. Ninth edition. Library of congress cataloging.202 pp.
3. Hadi M A , Kawan M H. (2016).Diagnosis Of *Toxocara canis* In Dogs In Baghdad By PCR Technique. International Journal of Recent Scientific Research. 7(6): 12169-12173.
4. Jacobs D E, Zhu X, Gasser R B, Chilton N B. (1997). PCR-based methods for identification of potentially zoonotic ascaridoid parasites of the dog fox and cat. ActaTropica.68: 191- 200.
5. Khademvatan S h, Fakher R, Mahdi T, Rahman A, Mahmoud H. (2013). PCR-Based Molecular Characterization of *Toxocaraspp.* Using Feces of Stray Cats: A Study from Southwest Iran. PLOS ONE |www.plosone.org|, 8(6):1-6.
6. Khatun Monjila , Nurjahan Begum , Abdullah Al Mamun , Motahar H M , Shakif Ul-Azam.(2014). Coprological study of gastrointestinal parasites of captive animals at Rangpur Recreational Garden and Zoo in Bangladesh.Journal of Threatened Taxa. 6(8): 6142–6147.
7. Moudgil A D, Singla L D, Singh M P. (2017). Internal transcribed spacer sequence based molecular confirmation and drug efficacy assessment against *Toxascaris leonina* (Linstow, 1909) infection in Asiatic lions (*Panthera leopersica*). Helminthologia. 54(2): 152 – 156.
8. Okulewicz A, Perec-Matysiak A, Buńkowska K, Hildebrand J. (2012). *Toxocara canis*, *Toxocaracati* and *Toxascaris leonina* in wild and domestic carnivores. Helminthologia. 49: 3 – 10.
9. Okulewicz A, Lonc E, Borgsteede F H M. (2002).Ascarid nematodes in domestic and wild terrestrial mammals.Polish Journal Veterinary Sciences. 5: 277 – 281.
10. Opara M N, Osuji C T , Opara J A. (2010).Gastrointestinal Parasitism In Captive Animals At The Zoological Garden, NekedeOwerri, Southeast Nigeria. Report and Opinion. 2(5): 21-28.
11. Radhy A M, Khalaf J M, Faraj AA. (2013). Some Gastro-Intestinal Protozoa Of Zoonotic Importance Observed In Captive Animals Of Al- Zawraa Zoo In Baghdad. International Journal of Science and Nature. 4(30): 567-570.
12. Sambrook J. ( 1989). Molecular Cloning: A Laboratory manual. Second Edition.; (Plainview, New York: Cold Spring Harbor Laboratory Press). 2028pp.

13. Thienpont E, Rochette F, Vanparijs O. (1986). Diagnosing helminthiasis by coprological examination. Turnhoutsebaan 30, 2340 Beerse, Belgium). Available from: Veterinary Laboratory Services; Unit 11. Station Road, South water, Sussex RH 13 7HQ. 137pp.
14. Tom N. (2006). Modified Wisconsin Sugar Flotation Method. VPTH 603 Veterinary parasitology; <http://cal.vet.upenn.edu/projects/parasit06/website/modWis.htm>
15. Uga S, Minami T, Nagata K. (1996). Defecation habits of cats and dogs and contamination by *Toxocara* eggs in public park sandpits. Amer. J. Trop. Med. Hyg, 54 (2): 122-126.
16. Virendra K T, Maiti S K, Aditi A D. (2014). Prevalence of gastro-intestinal parasites in captive wild animals of Nandan Van Zoo, Raipur, Chhattisgarh. Veterinary World. 7:448-451.

**Copyright: © 2018 Society of Education.** This is an open access article distributed under the Creative Commons Attribution License, which permits unrestricted use, distribution, and reproduction in any medium, provided the original work is properly cited.