



ORIGINAL ARTICLE

Ultrasonographic Survey of Myometrium Uterus Thickness in Diestrus Phase in Cross Bred Sarabi Cattle

Assadnassab Gh¹, Rahmani A², Kave AA¹, Jafari M³

1- Department of Clinical Science, Faculty of Veterinary Medicine, Tabriz Branch, Islamic Azad University, Tabriz, Iran (corresponding author:)

2- Private Veterinary Medicine, (DVM), Bukan, Iran

3- Private Veterinary Medicine, (DVM), Urmie, Iran

ABSTRACT

The aim of this study is measurement uterus thickness in diestrus phase in cross bred Sarabi cattles by ultrasonography. Special uterus structure is surveyed by Ultrasonography operations in twenty cross bred Sarabi cattles. In two dimensional scans, thickness of myometrium uterus at down-up axis length was measured. Median and standard deviation of the upper and lower thickness of myometrium uterus around of the lumen duct were 0.593 ± 0.05 and 0.513 ± 0.04 cm respectively. Also shows that the uterus in this phase has had a special laxity.

Keywords: Diestrus, Sarabi cattles, Ultrasonography, Uterus

Received 09/10/2013 Accepted 02/12/2013

©2013 Society of Education, India

INTRODUCTION

Genital organ, especially uterus plays a significant role in descendant survivorship, and without suitable efficient of this organ, cow will not able to continue descendant multiplication. Therefore, correct recognition of these components and familiarity with function of this system seems necessary.

There are many methods in order to study reproductive organ of cow that one of these methods is ultrasonography usage in normal and diseases related to it. Anatomical and physiological evaluations can be done by ultrasonography methods [1,2,3,4,5].

Ultrasonography is used as a prominent diagnosis technic in veterinarian and one of the usages of this method is diagnose survey of cow genital organ status that can display a part of considered problems in this field [6]. By this technic we can recognition and understanding of pregnant conditions, existence of diseases and role of environmental factors in them [7,8,9]. So, in this study we will try to study ultrasonography status of uterus and its thickness in cross bred Sarabi cattle in diestrus phase that is one of the estrus cycle steps and also we will conclusion measure structure of it by two-dimensional ultrasonography.

Uterus is protected by wide ligament that in fact is two layer fold of peritoneum and starts from under lumbar and sticks to edge of pelvis. This ligament protects uterus horn and cause the sticking of body edge of uterus. This ligament has smooth muscles and place vessels and nerves of uterus in itself. Uterus stretched from rumen back bag toward intestines and is contacted with urinary bladder in under part. Tissue anatomy of uterus wall consists of three layers, namely: Endometrium, Myometrium and perimetrium.

Uterus endometrium consists of two parts of surface layer that functional layer and basal layer. Uterus Myometrium is a very thickness layer that consists of linear and convoluted flat muscular brands which is divided into several incomplete layers by interlocking tissue. Among this layer, there are blood vessels [1]. Perimetrium forms the most external and the thinnest layer and is an interlocking layer [1,10,11].

Transrectal ultrasonography is access by probe that can place it inside rectum . Probes with 10cm length, 3cm height and 2 cm width can be placed inside cow rectum without problem. Uterus body scans usually is done in longitudinal axis that can be achieved by place transducer in forehead status of cervix. It is acquired by spin transducer in clockwise direction and vice versa in two part of separation of horn branches and also along with the body of them. The muscular various layers produce different signal by

the way of echogenicities and they're broken up from hyperechoic endometrium that through more inner anechoic uterus lumen. Of course, central muscular layers are not distinguished very well [5,12,13].

The uterine wall appears as a gray structure of moderate echogenicity. The peritoneal border of the uterus can be seen as a thin, hypoechoic line. In the center of the uterus a small area of high echogenicity can sometimes be found. It is caused by reflections from the echoic surface of opposing layers of the endometrium which lie in close apposition in the empty uterus and project as an echoic spot when seen in section or as anechoic line when viewed longitudinally. The structure of the uterine wall is homogenous during diestrus. When a linear ultrasound probe is positioned dorsally above the uterus and the sound beam is directed dorso-ventrally a longitudinal section of the organ is obtained. The latter is a distinct narrow, hypoechoic line which separates the uterine wall from the usually somewhat more echoic surrounding tissue.

The section through the uterine wall contains granular, variably structured shades of echogenicity. In the center of the organ the appositioned surfaces of the luminal epithelium often produce a hyperechoic line. This runs along the middle of the uterine section, from the tip of the horns up to and through the cervix. Large, coherent and anechoic fluid accumulations are not normally seen during diestrus [12,13].

MATERIALS AND METHODS

In refer to cow herds, 20 mature cross bred Sarabi cattles with tri-obstetric (weigh about 350-500kgs) in diestrus phase of estruse cycle were selected. We must know of estrus time in these animals. In order to assurance of place animal in this phase the time of estrus after and before of selection must be notated.

After preparing of work conditions, each cow physically was strained with rope and inside of cage. The feces were brought out from rectum. Feces and fecal gas; bubbles hinder the transmission of ultrasound waves. The absorption of sound waves by fecal mailer lying between the probe's scanning window and the rectal wall will result in the appearance of black stripes in the depth of the image. The rectum must therefore be evacuated. Used ultrasonography special gel on probe contacted surface and it was placed inside a plastic glove. Then, we stick this glove to probe by plastic glue until liquids and intestines contents didn't have any destructive effect on it. Gel must be placed in such ways that encompass all of probe portrait surface and there were no air between gels and glove and also between probe and connected surface of rectum, until it didn't produce respective artifacts [12,13].

Probe should be in carriers hand in such a way that probe surface was placed near to reproductive organs in connects to rectum. By probe 6-8MHz linear (if it is necessity, we can help from 5-7.5MHz probe) Pie Medical apparatus made of Esaote company, ultrasonography operation was done by rectal district with finding suitable approach. The probe introduced through the anus. The probe's scanning window is directed ventrally while it slides cranially along the rectal floor. Probe was directed by anus into rectum and was entered as foreside in so far as bladder (urinary bladder) can be observed. After visualization of the urinary bladder the ultrasound probe is advanced cranially until the uterus appears on the screen. The probe is placed dorsally on the uterus at the level of uterus body.

Also, it was rolled in both directions as laterally with angle 45 degree until uterus was observed on monitor. Its better ultrasonography operation be done in a dark place until the power of distinguish and resolution of ultrasonography images be increased.

After ending sonography operation, plastic cover of probe was brought out. Then, it was cleared and washed. Uterus body structures in standard ultrasonography operation were determined and measurement of myometrium uterus thickness in lower- upper axis length was done (fig 1and fig 2). The record of images and their printing were done with Sony printer and video. If probe be entered in rectum skillfully, serious damages won't be occurred. Incitation of rectum mucous leads to concise bloodshed that generally had not any serious damage. In this study the upper and lower myometrium of uterus around of the lumen duct was measured (fig 2).

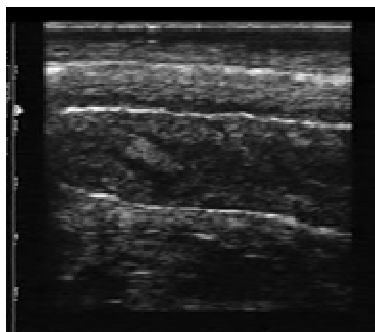


Figure1: Sample of uterus ultrasonography images

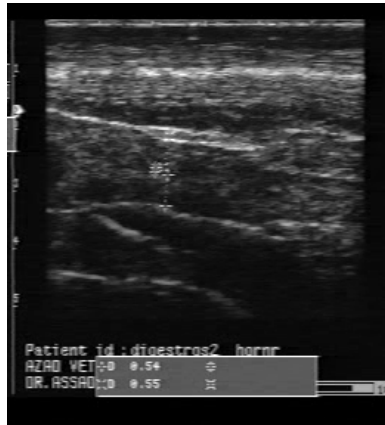


Figure 2: Sample of measurement

RESULTS OF THE STUDY

In table 1, statistical description of acquired data of myometrium uterus thickness is indicated with accounting median, standard deviation.

Table 1: statistical description of acquainted data of myometrium uterus thickness in 20 cross bred Sarabi cattle

Area of the study	The median of data	Standard deviation
Upper myometrium	0.593	0.05
Low myometrium	0.513	0.04

In this study, the structure of various layer of muscular of myometrium uterus shows various signals and is easily diagnosed from hyperechoic endometrium and from more inner anechoic of uterus lumen. Myometrium uterus can be seen in hyperechoic status. Of course, these central muscular layers aren't distinguishable very well.

In this study, median and standard deviation the upper and lower myometrium of uterus thickness around of the lumen duct were 0.593 ± 0.05 and 0.513 ± 0.04 cm respectively.

DISCUSSION

Ultrasonography of cow reproductive organ has been posed as one of diagnostic imaging subjects in veterinary and it is used in the diagnosis of pregnancy, uterus survey and ovaries activities in cow [7,8,9,11,14,15,]. Also, ultrasonography technics is used in breeding subjects and diseases related to it [1,6,11,12].

Khan in his book has done uterus ultrasonography in various steps of estrus cycle and has reported measurement of these components [13]. Also, Fissore during his studying has surveyed uterus in various states [15]. Arthur and Marrow have pointed to ultrasonography of components of reproductive organ [1,11].

In conducted studies on ultrasonography and reproductive organ measurements is indicated, specially uterus in cow [1,13], but this was not observed in cross bred Sarabi cows that are different body fitness with another cattle.

Various methods are presented for assessment of uterus status in cow, in this survey, ultrasonography transrectal method is more efficient by using linear probe with high frequencies that our survey contains this material and this is adapted with reports of other researchers [1,6,12,13].

About cross bred Sarabi cattles, uterus thickness is different than the same amount that one of the reasons this non-adaption can be related to intended animal reproductive and body structures.

Ultrasonography is one of the most important and the best technics of diagnostic for uterus structure in veterinary science that can be responded to many problems in this field. Although, there are various technics for acquiring this task, but it seems that one of the best technics in this field is using ultrasonography devices. This survey shows that different parts of cow's uterus are portrayed by ultrasonography methods that is adopted with others findings [1,5,6,13].

With recognizing structure of uterus ultrasonography, produced in it accounted as disease with introducing mentioned changes and this help important step in treatment of these diseases, and this task cause to optimized using genetic potential of cattle during their economic life [2,3,7]. In this study

the upper and lower myometrium of uterus around of the lumen duct was measured and median and standard deviation of the upper and lower myometrium of uterus thickness around of the lumen duct were 0.593 ± 0.05 and 0.513 ± 0.04 cm respectively. This show the layers of myometrium thickness are different with them and the upper layer has a little thickness than the low layer.

Ultrasonography measurement may be important because of doesn't having anatomical methods problems that is possible by using materials or special methods as freezing which produce changes in uterus structures size.

According to intended findings in this study, we can conclude that ultrasonography is an important diagnostic tool in uterus ultrasonography and specially, is helpful on assessment its status during reproductive cycle.

REFERENCES

1. Arthur GH, Noakes DE, Pearson H, Parkinson TJ (1996) Veterinary reproduction and obstetrics. Saunders WB company, Philadelphia, pp:12-24,51-89, 365-366.
2. Edmondson AJ, Fissore RA, Pashen RL, Bondurant RH (1986) The use of Ultrasonography for the study of the bovine reproductive tract. I. Normal and pathological ovarian structures. *Animal Reproduction Science* 12(3):157-165.
3. Izaike Y, Suzuki O, Shimada K, Takenouchi N, Takahashi M (1991) Observation by Ultrasonography of embryonic loss following the transfer of two or three embryos in beef cows. *Theriogenology* 36(6):939- 947.
4. Reef VB (1998) Equine diagnostic ultrasound. Saunders WB company, Philadelphia pp:10-20,90-140.
5. Thomag N (1995) Veterinary diagnostic ultrasound. Saunders WB company, Philadelphia pp: 1-50.
6. Roberts SJ (1999) Veterinary obstetrics and Genital Disease. 2nd ed., CBC Publishers and Distributors, New Dehli, pp:1-41.
7. Filteau V, DesCoteaux L, Williams EI (1998) Predictive values of early pregnancy diagnosis by ultrasonography in dairy cattle, Proceedings of the Thirty-First Annual Conference American Association of Bovine Practitioners. Spokane, Washington, USA 24(26):170-171.
8. Totey SM, Singh G, Taneja M, Talwar GP (1991) Ultrasonography for detection of early pregnancy following embryo transfer in unknown breed of cows. *Theriogenology* 35(3):487-497.
9. Willard ST, Sasser RG, Gillespie JC, Jaques JT, Welsh TH, Randel RD (1994) Methods for pregnancy determination and the effects of body condition on pregnancy status in Rocky mountain elk. *Theriogenology* 42(7):1095-1102.
10. Dyce KM, Sank WD (1996) Textbook of veterinary Anatomy. Saunders, London, pp:657-677.
11. Morrow D (1986) Current therapy in Theriogenology. Saunders WB company, Philadelphia pp:95-100, 679-684.
12. Goddard PJ (1995) Veterinary ultrasonography. CAB international pp:1-12, 87-104, 165-275 .
13. Kann W (1994) veterinary reproductive ultrasonography. Mosby- wolf, London pp:82-135.
14. Chaffaux S, Reddy GNS, Valon F, Thibier M (1986) Transrectal real-time ultrasound scanning for diagnosing pregnancy and for monitoring embryonic mortality in dairy cattle. *Animal Reproduction Science* 10(3):193-200.
15. Fissore RA, Edmondson AJ, Pashen RL, Bondurant RH (1986) The use of Ultrasonography for the study of the bovine reproductive tract. II. Non-pregnant, pregnant and pathological conditions of the uterus. *Animal Reproduction Science* 12(3):167-177.

Citation of This Article

Assadnassab Gh, Rahmani A, Kave AA, Jafari M. Ultrasonographic Survey of Myometrium Uterus Thickness in Diestrus Phase in Cross Bred Sarabi Cattle.. Adv. Biores. Vol 4[4] December 2013: 47-50