

## CASE REPORT

# An Atypical Complication of Dengue Haemorrhagic Fever: Acute Intracranial Hemorrhage

<sup>1</sup>Jitendra Singh, <sup>2</sup>Anju Dinkar, <sup>3</sup>Virendra Atam, <sup>4</sup>Ravi Misra, <sup>5</sup>Saurabh Kumar

<sup>1</sup>Senior Resident, Department of Medicine, King George Medical University, Lucknow, UP, India

<sup>2</sup>Senior Resident, Department of Microbiology, Sanjay Gandhi Postgraduate Institute of Medical Sciences, Lucknow, U.P, India

<sup>3</sup>Professor, Department of Medicine, King George Medical University, Lucknow, UP, India

<sup>4</sup>Professor and Head, Department of Medicine, King George Medical University, Lucknow, UP, India

<sup>5</sup>Junior Resident, Department of Radiodiagnosis, King George Medical University, Lucknow, UP, India

### ABSTRACT

*Dengue is arboviral infection transmitted by Aedes aegypt mosquitoes found in tropical and subtropical climates. Dengue infection can manifest a variety of systemic complications ranging from self-limiting and mild to life-threatening conditions. Recently it is seen that clinical profile of dengue is changing, and neurological manifestations are being reported more frequently. One of them is intracerebral hemorrhage which is reported very rarely. Hereby we reported a 62-year old male of dengue hemorrhagic fever who was found to have intracerebral bleed on investigations. He recovered almost completely on conservative treatment.*

**Keywords;** Dengue fever, Dengue hemorrhagic fever, Encephalopathy, Intracerebral bleed, Intracranial hemorrhage

Received 28/04/2015 Accepted 04/07/2015

©2015 Society of Education, India

### How to cite this article:

Jitendra S, Anju D, Virendra A Ravi M, Saurabh K. An Atypical Complication of Dengue Haemorrhagic Fever: Acute Intracranial Hemorrhage. Adv. Biores. Vol 6 [4] July 2015: 148-151. DOI: 10.15515/abr.0976-4585.6.4.148151

## INTRODUCTION

In India, cases of dengue fever start to increase from August onwards and decrease as winter sets in. All four distinct dengue viruses (dengue 1-4) have similar clinical syndrome. The typical presentation includes fever with macular rashes, headache, retro orbital pain along with the severe myalgia that gave rise to colloquial designation "break-bone fever". In rare cases second infection with different serotype from primary infection leads to dengue DH with severe shock [1]. Intracerebral hemorrhage in our case is an unusual presentation of central nervous system involvement in dengue fever and only few cases are reported in literature [2].

## CASE REPORT

A 62-year-old male, non alcoholic labourer was referred to emergency department of our institution with chief complaints of fever with rashes for 8 days, left sided body weakness and altered sensorium for 2 days. On enquiry his relatives told that initially patient was admitted in a private hospital for the complaints of fever with rashes all over the body predominantly over limbs. Even though condition of patient was deteriorating and platelets counts was decreasing continuously. Patient was then referred to tertiary care hospital (KGMU). On the day of admission patient was in unconscious state with a Glasgow coma score (GCS) of 8 (E2M4V2). The patient had no signs of meningeal irritation and his cranial nerves examinations could not be done. On general examination patient had no pallor or icterus. He was febrile (101°F). His pulse rate- 100/ min normovolumic and regular, B.P- 110/80 mmHg and respiratory rate was-20/min. The tourniquet test was positive. He had no history of hypertension, diabetes mellitus, cardiovascular disease, atherosclerosis, trauma, seizure, drug abuses, coagulopathy, alcoholism, or any similar episodes of altered sensorium in past. Cardiovascular, respiratory and abdominal examinations did not reveal any abnormality. During hospitalisation and previous available laboratory investigations of patient are summarised in table [1]. Enzyme-linked immunosorbent assay for human immunodeficiency

virus, Australia antigen for Hepatitis B and antibody against Hepatitis C virus were negative. Serology of enteric fever and smear examination for malaria parasite were negative. Urine routine and microscopy was also normal. Serology (IgM antibody) for dengue infection was positive. Electrocardiography and chest X-ray were within normal limit. Plain Computed Tomography scan of head showed right sided intracerebral bleed. (Figure; 1A, B and C) Patient was managed conservatively with twelve units' transfusion of platelets during hospitalisation. The patient showed gradual improvement. Due to financial constraints of patient, he was discharged on request. At the time of discharge he was fully conscious and oriented with power 3/5 in left upper and 3/5 in left lower limb. Limbs physiotherapy with general supportive care was advised. After three months of follow up outpatient door, he recovered almost fully.

## DISCUSSION

Several clinical settings have described the association of neurological manifestations with dengue fever. The relationship between DHF and atypical neurological disturbances was first described in 1976 [3]. The true incidences of dengue associated neurological complications are not clearly mentioned because of only hospital based cases are reported in most of literature.

On the basis of last few years' studies, neurological complications occur in 0.5–6% of the cases with dengue fever [4]. Various neurological manifestations reported in dengue fever are summarised into three categories: (I) manifestations due to neurotrophic effect of virus: rhabdomyolysis, myositis, myelitis, meningitis and acute encephalitis; (II) systemic manifestations of dengue fever: hypokalemic paralysis, papilledema, encephalopathy and stroke (hemorrhagic and ischemic) and (III) post-infection manifestations: fatigue syndrome, acute disseminated encephalitis (ADEM), encephalomyelitis, myelitis, neuromyelitis optica, optic neuritis, Guillain-Barre syndrome, phrenic neuropathy, long thoracic neuropathy, oculomotor palsy and maculopathy [5]. The exact pathogenesis of neurological hemorrhagic complications is not well known. Impairment of platelet function can also increase the risk of vascular fragility which may lead to hemorrhage. However possible mechanism of bleeding diathesis in dengue infection may be due to vasculopathy, thrombocytopenia and platelet dysfunction [6]. Low platelets count in dengue fever is due to both from decreased production and increased destruction which correlates with the clinical severity of DHF [7]. Since the patient was native of endemic area, and his clinical features with lab investigations (low platelets count and intracranial hemorrhage) suggested a clinical picture of dengue fever. Apart from more common cause of intracranial hemorrhages, we also ruled out amyloid angiopathy, neoplasm and vascular malformation. Then final diagnosis of intracranial hemorrhage due to dengue fever was made when IgM antibodies against dengue virus was positive.

Table1; Patient's laboratory parameters during hospitalization

Laboratory parameters with date	During other hospital			During our hospital (KGMU)				
	22.10.12	23.10.12	24.10.12	26.10.12	28.10.12	29.10.12	30.10.12	01.11.12
Hb(g/dl)	13.5	10.4	10.8	10.4	11.0	10.8	11.5	13.0
TLC (103/ $\mu$ L)	9.77	6.89	8.0	9.1	8.8	8.2	7.8	8.0
DLC (%)	N80L09	N70L24	N67L22	N71L15	N70L14	N72L14	N79L16	N68L15
PC (103/ $\mu$ L)	8.0	6.0	12.0	66.0	50.0	90.0	120.0	155
HCT (%)	40.1	31.3	32.3	31.1	32.5	31.8		32
S.Na+(mmol/L)	134		138	142	138		136	140
S.K+(mmol/L)	3.5		3.4	2.8	4.2		4.0	4.3
S.Urea(mgdl)	49.4			35.1		38.4		36
S.Creat (mgdl)	0.95			0.90		1.2		0.9
RBS(mg/dl)	112	100		92	98	110	118	112
PTT (seconds)	25			26				
PT(in seconds, control 12.1 s)	14.9			14.8		13.2		12.2
INR (seconds)	1.31			1.24		1.2		1.2
ALT (IU/L)		92.0		40				46
AST (IU/L)		73.0		42				40
S.ALP		70.0		70				80
S. Protein(g/dl)		7.2		7.0				6.4
S. Albumin(g/dl)		3.5		3.5				3.2

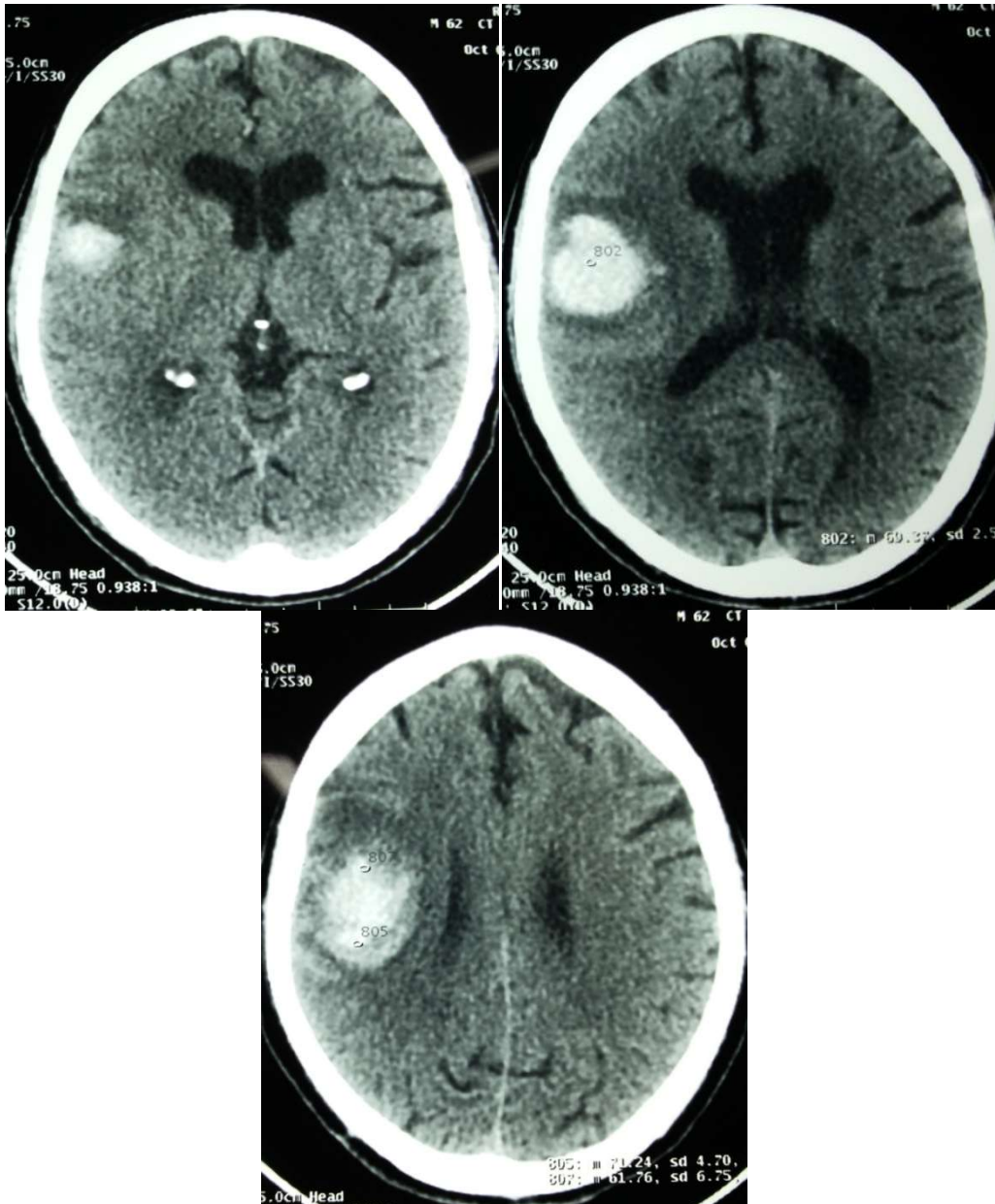


Figure1 (A, B and C); Acute intra-axial bleed in right fronto-parieto-temporal region with mass effect and midline shift of 4 mm towards left side

**CONCLUSION**

With the above description it is clear that a dengue fever can causes a variety of neurological manifestations in endemic countries. Our case report highlights the potential danger of dengue fever, so treating physician must be aware of the development of atypical neurological manifestations. Early diagnosis and management with prompt supportive care can reduce the morbidity and mortality of the patients by preventing neurological disabilities.

**REFERENCES**

1. Peters CJ. (2012). Infection caused by arthropod- and rodent- borne viruses. In: Longo DL, Fauci AS, Kasper DL, Hauser SL, Jameson JL, Loscalzo J et al., editors. Harrison's principles of internal medicine. 18th ed. New York:McGraw Hill; p1617-1632
2. Kumar J, Kumar A, Gupta S, Jain D.(2007).Dengue haemorrhagic fever: an unusual cause of intracranial haemorrhage. J Neurol Neurosurg Psychiatry; 78(3): 253.
3. Sanguanserm Sri T, Poneprasert B, Phornphutkul B, et al. (1976). Acute encephalopathy associated with dengue infection. Bangkok: Seameo Tromped:10-11
4. Hendarto SK, Hadinegoro SR. (1992). Dengue encephalopathy. Acta Paediatr Jpn 1992;34:350-7

5. Murthy J. (2010). Neurological complications of dengue infection. *Neurol India*;58:581-4
6. Trung DT, Wills B. (2010). Systemic vascular leakage associated with dengue infection - the clinical perspective. *Curr Top Microbiol Immunol*;338:57-66
7. Noisakran S, Chokephaibulkit K, Songprakhon P, Onlamoon N, Hsiao HM, Villinger F, *et al.* (2009). A re-evaluation of the mechanisms leading to dengue hemorrhagic fever. *Ann N Y Acad Sci* 2009;1171:E24-35