

## CASE STUDY

# Therapeutic Efficacy of Ayurvedic Management in Ascites: A Case Study

Kajal Patel <sup>1</sup>, Harish Daga <sup>2</sup>

<sup>1-2</sup>Department of Shalya Tantra, Parul Institute of Ayurved, Parul University, Vadodara, Gujarat

**Corresponding Author:**

Dr. Kajal Patel

Email id: [kajal.kkpatel8442@gmail.com](mailto:kajal.kkpatel8442@gmail.com)

### ABSTRACT

Ascites, known as *Jalodara* in Ayurveda, is a pathological condition characterized by fluid accumulation in the peritoneal cavity, often linked to liver cirrhosis, heart failure, or malignancies. Conventional treatments rely on diuretics, paracentesis, or portosystemic shunts, which provide symptomatic relief but do not address underlying pathophysiology. This study presents a single-patient case study using an Ayurvedic multimodal approach involving herbomineral formulations, *Nitya Virechana*, and *Basti* therapy. The patient, a 60-year-old female with liver cirrhosis-induced ascites, underwent Ayurvedic treatment with significant improvements in abdominal girth, weight, and biochemical parameters. This case study highlights Ayurveda's potential in ascites management by addressing the root cause rather than merely alleviating symptoms.

**Keywords:** Ascites, *Jalodara*, Ayurvedic Management, *Nitya Virechana*, *Basti* Therapy, Liver Cirrhosis

Received 24.08.2025

Revised 01.10.2025

Accepted 11.11.2025

### How to cite this article:

Kajal P, Harish D. Therapeutic Efficacy of Ayurvedic Management in Ascites: A Case Study. Adv. Biores. Vol 16 [6] November 2025. 528-535

## INTRODUCTION

Ascites is a condition of pathological fluid accumulation in the peritoneal cavity, most commonly caused by portal hypertension due to liver cirrhosis. The conventional approach includes sodium restriction, diuretics, and paracentesis, which may provide symptomatic relief but fail to prevent recurrence.[1][9] *Ayurveda* considers ascites as *Jalodara*, one of the eight *Udara Rogas*, caused by *Prakupita Vata* accumulating in the peritoneal cavity due to impaired *Agni* (digestive fire), improper dietary habits, and hepatic dysfunction.[3][4]. This study investigates the efficacy of herbomineral drugs, *Basti* therapy, and *Nitya Virechana* in managing cirrhosis-induced ascites, focusing on biochemical, symptomatic, and radiological improvements.

## MATERIAL AND METHODS

### Patient Information

- **Age/Sex:** 60-year-old female
- **Clinical Presentation:** Progressive abdominal distention (3 months), breathlessness, exertional dyspnea, and generalized weakness.
- **Medical History:** Diabetes mellitus (3 years), right-sided pleural effusion.
- **Family History:** No similar conditions reported.

### Diagnosis

- **Clinical Findings:**
  - **Abdominal distention**
  - **Fluid thrill test:** Positive
  - **Shifting dullness:** Positive
  - **Bilateral pedal edema:** ++

- **Vitals:** BP - 130/90 mmHg, HR - 90/min, RR - 24/min, Temp - 96°F
- **USG Findings:**
  - Liver cirrhosis with **gross ascites**
  - Moderate right-sided pleural effusion
  - Peri-gastric collateral formation

### Ayurvedic Treatment Protocol

#### A. Internal Medication

Medicine	Dosage
<i>Patoladi Kashaya</i>	30 ml BD
<i>Arogyavardhini Vati</i>	2 TID
<i>Makoi Arka</i>	20 ml BD
<i>Trivruta Avaleha</i>	2 tsp in the morning
<i>Punarnavasthaka Kwatha</i>	20 ml BD
<i>Chyawanprasha</i>	1 tsp OD
<i>Bhumyamlaki Churna</i>	1 tsp BD
<i>Egg Yolk Basti</i>	Administered daily

**Table 1:** Ayurvedic Internal Medications and Panchakarma Interventions Administered During the Treatment Period

#### Panchakarma Therapies

- **Nitya Virechana:** *Trivruta Avaleha* (2-3 tsp daily for 15 days)
- **Basti Therapy:** Egg yolk, honey, and *Saindhava*-based *Basti* (administered daily for 18 days)
- **Dietary Modifications:** *Peya* (rice water), *Vilepi* (gruel), *Aja Dugdha* with *Sunthi Jala* (for hydration and metabolic correction)

## RESULTS

### Biochemical and Clinical Observations

Parameter	Pre-Treatment	Post-Treatment
Abdominal girth	98 cm	83 cm
Weight	59 kg	45 kg
Hemoglobin	7.3 g/dL	8.2 g/dL
Serum Albumin	3.15 g/dL	3.49 g/dL
Fluid output (average)	700 ml/day	1000 ml/day

**Table 2:** Comparison of Clinical and Biochemical Parameters Before and After Ayurvedic Treatment  
The patient demonstrated marked clinical, biochemical, and functional improvement following the Ayurvedic intervention. A significant reduction in abdominal distension was observed, as evidenced by a consistent decrease in abdominal girth at all measured levels. This regression indicates effective mobilization and elimination of ascitic fluid, reflecting successful management of Jalodara through Ayurvedic modalities.

#### Fluid Input and Output

Date	Fluid Input (Milk)	Fluid output
18 June 2024	200 ml	600ml
19 June 2024	500 ml	950 ml
20 June 2024	1000 ml	850 ml
21 June 2024	750 ml	500 ml
22 June 2024	600 ml	800 ml
23 June 2024	500 ml	1000 ml
24 June 2024	700 ml	700 ml
25 June 2024	600 ml	650 ml
26 June 2024	1200 ml	1700 ml
27 June 2024	500 ml	1500 ml
28 June 2024	600 ml	1480 ml
29 June 2024	800 ml	1190 ml
30 June 2024	800 ml	700 ml
1 July 2024	400 ml	820 ml
2 July 2024	400 ml	400 ml
3 July 2024	600 ml	650ml
4 July 2024	400 ml	800ml
5 July 2024	400 ml	810ml

**Table 3 :** Daily Fluid Intake and Output Record During the Treatment Period

Body weight showed a substantial reduction over the treatment period, suggesting a decrease in pathological fluid accumulation rather than loss of lean body mass. This finding correlates with increased daily fluid output observed during therapy, indicating enhanced elimination of excess fluid through physiological pathways emphasized in Ayurveda, particularly the Purishvaha Srotas.

#### Hematological Investigations

	22-03-2024	20-06-2024	28-06-2024
Hb	7.8g/dl	7.3g/dl	8.2g/dl
RBC	4.25mill/cmm	3.79mill/cmm	4.25mill/cmm
Hematocrit	27.4%	22.5%	24.8%
MCV	64.5fl	59.2fl	58.5fl
MCH	18.2pg	19.3pg	19.4pg
MCHC	28.5g/dl	32.6g/dl	33.3g/dl
RDW	17.1%	23.5%	22.5%
WBC	6500/cmm	7700/cmm	7700/cmm
Platelet	265000/microlit	184000/microlit	218000/microlit
Sr. Creatinine		0.86mg/ml	0.76mg/ml
Blood Urea		30.0mg/dl	15.52mg/dl
S. Uric Acid		4.85mg/dl	4.96mg/dl
SGPT		30.06U/L	21.22U/L
SGOT		44.20U/L	40.66U/L
Albumin		3.15gm/dl	3.49gm/dl
Albumin/Globulin Ratio		1.19gm/dl	1.25gm/dl
Alkaline Phosphate		126.3U/L	100.1U/L
Bilirubin Direct		0.38mg/dl	0.35mg/dl
Bilirubin Indirect		0.40mg/dl	0.39mg/dl
Bilirubin Total		0.78mg/dl	0.74mg/dl
Globulin		2.63gm/dl	2.77mg/dl
Protein		5.78gm/dl	6.26gm/dl

**Table 4 : Serial Hematological and Biochemical Investigations Showing Treatment Response**

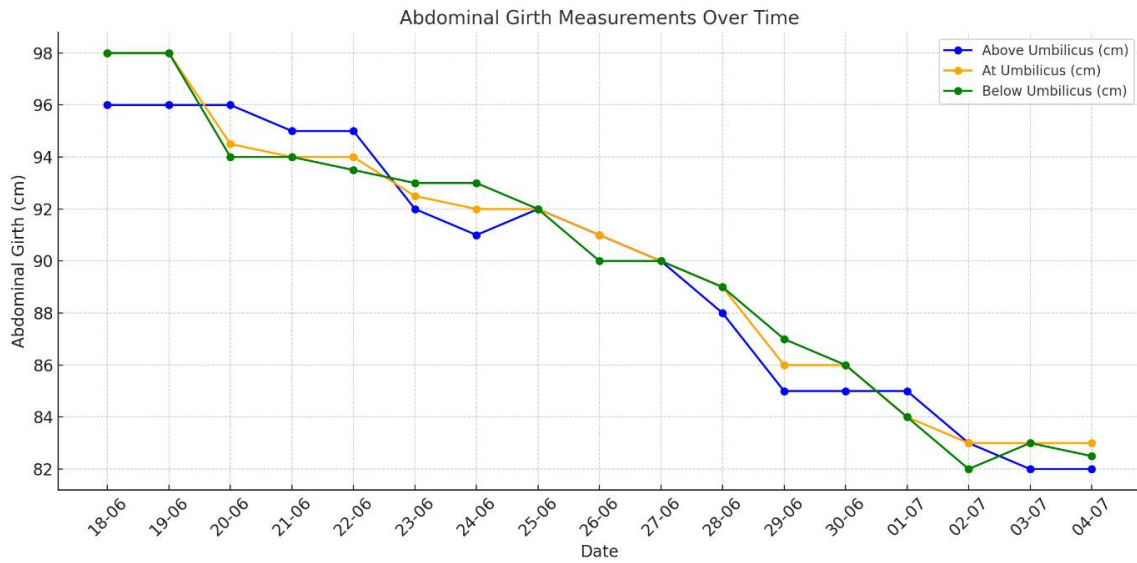
Hematological parameters revealed gradual improvement, with an increase in hemoglobin levels and stabilization of red blood cell indices, suggesting improved nutritional status and reduced hemodilution following ascitic fluid reduction. Serum albumin levels showed a notable rise post-treatment, reflecting improved hepatic synthetic function and maintenance of oncotic pressure. This improvement is clinically relevant, as hypoalbuminemia is a major contributor to ascites formation in cirrhosis.

Renal function parameters remained within normal limits throughout the treatment period, indicating that fluid removal occurred without compromising renal function. Liver function tests showed stabilization and mild improvement in transaminase levels and alkaline phosphatase, suggesting hepatoprotective effects of the administered formulations. Total protein and albumin-globulin ratio also improved, supporting enhanced metabolic and hepatic activity.

Overall, the findings indicate that the integrated Ayurvedic approach led to effective reduction of ascitic fluid, improvement in liver function, and correction of metabolic imbalance. These results are consistent with earlier Ayurvedic case studies on Jalodara, which reported reduction in abdominal girth, improved appetite, and better biochemical profiles following therapies such as Nitya Virechana and Basti. Compared to conventional management that primarily offers symptomatic relief, the observed outcomes suggest that Ayurveda may contribute to sustained improvement by addressing the underlying pathophysiology of ascites.

#### Graphical Representation:

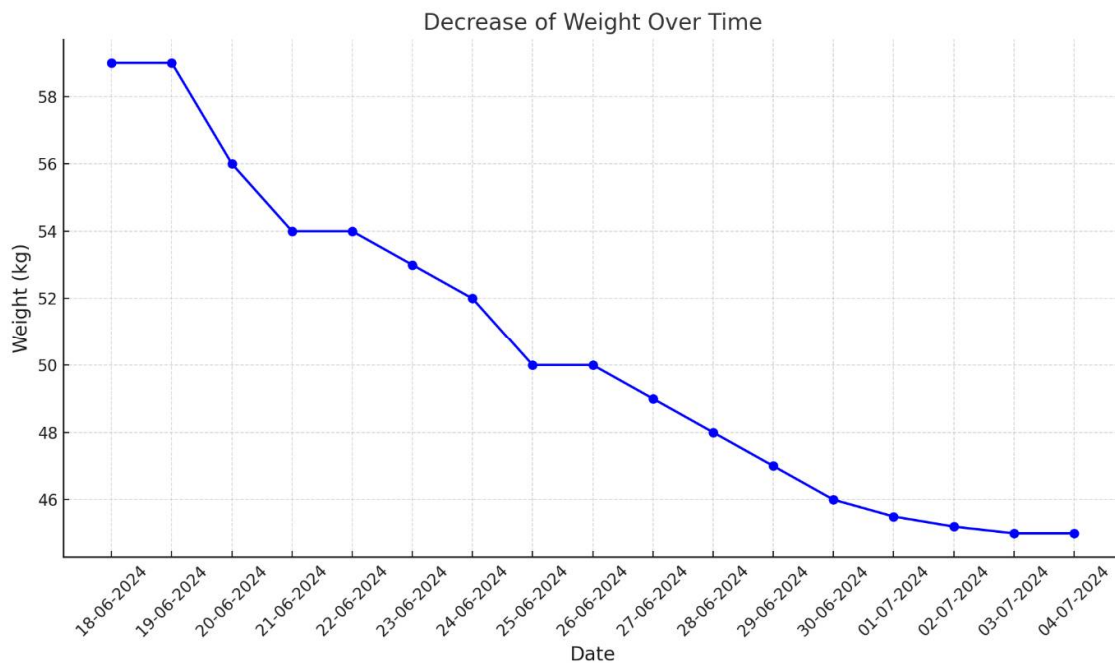
Bar graphs showing abdominal girth reduction and weight loss trends



**Graph 1: Graph Showing Reduction in Abdominal Girth at Different Levels Following Treatment**

There was marked improvement in the regression of abdominal girth. The Abdominal Girth before treatment was 96cm, 98cm, 98cm above umbilicus, at umbilicus and below umbilicus respectively. Abdominal Girth after treatment was 82cm,83cm,82.5cm above umbilicus, at umbilicus and below umbilicus respectively. The difference before and after treatment is 14cm,15cm,15.5cm above umbilicus, at umbilicus and below umbilicus respectively.

**Graph 1** demonstrates a marked reduction in abdominal girth at all three measured levels—above the umbilicus, at the umbilicus, and below the umbilicus—following Ayurvedic intervention. The abdominal girth showed a consistent decrease of approximately 14–15.5 cm across all measurement points, indicating significant regression of ascitic fluid and reduction in abdominal distension over the treatment period.



**Graph 2: Showing Change in Body Weight Before and After Treatment**  
**Chart 2**

The weight observed before treatment was 59kg.  
The weight observed after 15 days of treatment was 45kg.  
The difference observed before and after treatment was 14kg.

**Graph 2** illustrates a substantial decrease in body weight during the course of treatment. The patient's weight reduced from 59 kg before treatment to 45 kg after completion of therapy, reflecting a total reduction of 14 kg. This weight change corresponds with the observed increase in fluid output and supports effective mobilization and elimination of excess fluid accumulation.

The treatment resulted in a significant reduction in abdominal girth at all measured levels and a marked decrease in body weight, indicating effective regression of ascitic fluid. Improvement in hematological and biochemical parameters, particularly serum albumin and hemoglobin levels, was also observed, reflecting enhanced hepatic function and overall clinical status.

## DISCUSSION

The *Ayurvedic* management of ascites in this case emphasizes root-cause correction by regulating *Agni* (digestive fire), removing fluid through *Purishvaha Srotas*, and strengthening liver function.[3][4]

### 1. **Nitya Virechana (Daily Therapeutic Purgation)[3]**

- Eliminates excessive *Pitta* and *Kapha* accumulation.
- Stimulates hepatic detoxification and metabolism.[3][4]
- *Nitya Virechana*, a daily purgative therapy in *Ayurveda* helps in managing ascites by eliminating excess *pitta* and *drava dravya* helps in detoxifying liver and promoting fluid removal through *Purishvaha Srotas*. [5] In contrast, modern treatment like diuretics, paracentesis and surgical intervention focuses on symptom relief with risk of infection and electrolyte imbalances, while paracentesis provides temporary relief with the risks of infection and recurrence.

### 2. **Basti Therapy (Egg Yolk Basti)**

- Provides nutritional support (albumin, vitamin B12, essential fatty acids).[18]
- Maintains osmotic pressure and prevents *dhatu kshaya*. [3]
- Herbomineral Formulations
- *Arogyavardhini Vati*: Hepatoprotective, *Pitta*-pacifying.[7][25]
- *Patoladi Kashaya*: Diuretic and hepatoprotective.[7]

Ascites, a condition often linked with *cirrhosis* and *portal hypertension*, presents a challenge in clinical management. In ascites, the kidneys (renal pathway) and lymphatic system are the main routes for fluid elimination, though therapeutic interventions like diuretics and paracentesis are often necessary to manage the excess fluid that the body's natural elimination mechanisms cannot handle effectively. [9] But *ayurved* has emphasized on the *agni* as *agni* is the seat of *pitta* and in *jalodara* there is vitiation of *pitta* and to eliminate the fluid through *purishvaha srotas* rather than hampering the renal pathway.[3] As *virechana* is the best treatment modality for vitiated *pitta* and in this condition removal of extra fluid from peritoneal cavity through *purishvaha srotas* is beneficial. This is done through administration of *Trivruta avleha*. The use of *trivruta avleha* as *nitya virechana* helps in eliminating the excess fluid through the body, thus reducing abdominal distention and fluid accumulation. *Trivruta avleha* also helps in strengthening the *agni*, thus increasing digestive fire and better metabolism. [11][12][14]. There is *strotoavarodha* created by accumulation of excessive fluid in the *udara*, *trivruta* helps in opening these *srotas* and removes the excess fluid through the *purishvaha srotas*. To strengthen the *agni* after *nitya virechana sansarjana* karma is followed, patient was kept on diet of *peya* and *vilepi*, *ajadugdha* with *shunthi churna*. *Shunthi siddha* jala was administered for period of 17 days.

As said in *ayurveda* the first *chikitsa* should be opted as *nidana parivarjana*. So, the *pitta vardhaka ahara* like intake of *Katu* (spicy), *Snigdha* (oily), *Amla* (sour), and *Lavana* (salty) foods, *Madya* (alcohol) and intake of *dadhi*, *takra*, combined with *Chinta* (stress), *Krodha* (anger) should be avoided strictly. One should undergo *langhana* as there is excessive vitiation of *pitta* and the *agni* is hampered so to bring back *agni* in *sam avastha langhana* should be followed. The role of *aja dugdha* in case of *jalodara* is to do *rechana*, milk has *rechana guna* and helps to nourish *dhatu* as well as remove the vitiated *pitta* through *purishvaha srotas*. [3]

The management of ascites differs significantly between *Ayurvedic* and allopathic approaches, particularly use of diuretics, albumin infusions and paracentesis. Allopathic approaches focuses on the use of diuretics such as spironolactone and furosemide to promote fluid removal through kidneys.[1] While effective in reducing ascitic fluid prolonged use can lead to electrolyte imbalance, dehydration and renal dysfunction.[9][17] In contrast *Ayurveda* focuses on removing excessive fluid through *purishvaha srotas*, and enhancing digestive fire, while egg yolk *basti* focuses on maintain oncotic pressure by maintaining albumin level and SAAG level.

Overall, while allopathic treatments provide quick symptomatic relief, they often lead to dependency on medications or repeated invasive procedures. *Ayurveda* offers a more sustainable, holistic approach by

addressing fluid accumulation through digestive correction, hepatic support, and safe elimination therapies, thus targeting the root cause of ascites rather than just alleviating symptoms.

The outcomes observed in the present case study are in close agreement with previously published Ayurvedic and contemporary studies on the management of Jalodara (ascites). Earlier reports have documented that Ayurvedic interventions such as Nitya Virechana, Basti therapy, and hepatoprotective formulations lead to significant reduction in abdominal girth, body weight, and improvement in biochemical parameters in cirrhosis-induced ascites [11][12][13]. Classical Ayurvedic texts describe Jalodara as a disease originating from Agnimandya, Pitta dushti, and obstruction of Srotas, particularly involving Yakrit and Udara Pradesh (Charaka Samhita, Chikitsa Sthana). Acharya Charaka specifically emphasizes Virechana as the prime line of treatment in Jalodara for eliminating excess Drava and vitiated Pitta through the Purishvaha Srotas.[3] The present study supports this classical principle, as Trivruta Avaleha-based Nitya Virechana resulted in consistent increase in fluid output and marked reduction in abdominal distension.

Similar findings were reported by Bhagiya et al. and Sahebrao & Khilare [13][14], where daily purgation therapy led to effective mobilization of ascitic fluid without compromising renal function. This contrasts with modern diuretic therapy, which primarily acts through the renal pathway and is often associated with electrolyte imbalance, renal dysfunction, and recurrence [1][9].

The observed improvement in serum albumin levels in the present case correlates with earlier studies reporting that Ayurvedic formulations possessing Yakrit-uttejaka, Rasayana, and Brimhana properties help restore hepatic synthetic function[15][16]. Maintenance of albumin is clinically significant, as hypoalbuminemia plays a central role in the pathogenesis of ascites by reducing plasma oncotic pressure [17]

Thus, the findings of the present case study are consistent with both classical Ayurvedic doctrine and contemporary clinical evidence, supporting the role of Ayurveda as a holistic and sustainable approach in ascites management.

#### **Mode of action of Drugs used during the treatment:**

##### **Egg Yolk *basti***

The use of *Basti* therapy, especially with Egg Yolk *Basti*, is noteworthy for its nutritive and pacifying effects on the doshas involved in ascites. Egg yolk *basti* helps in providing the nutrition to the *dhatu*s, as in ascites there is severe *dhatu kshaya* is seen, egg yolk contains Albumin which is necessary for maintaining the osmotic pressure, it also contains Vit b12, Vit D, essential fatty acids which helps in the nourishment of *dhatu*s. Egg Yolk *basti* serves as both a nutritive and therapeutic enema ensuring direct absorption of nutrients while simultaneously pacifying aggravated *vata* and *pitta*.

##### **Arogyavardhini Vati**

*Arogyavardhini Vati* is known for its benefits especially to the liver. *Arogyavardhini* maintains the liver function and promotes balance as well as a healthy digestive system. Its main content is *Katuki* (*Picrorhiza kurroa* Royle ex Benth.) which acts as *Pitta Virechana* and acts on *Yakrita*.

##### **Makoi Arka**

The main ingredient of *makoi arka* is *Kakmachi* which helps in healthy functioning of liver and acts on all the three doshas *Vata*, *Pitta* and *Kapha*. The pharmacological attributes of *kakmachi* is it acts as hepato-protective, anti-oxidant, immunomodulatory.

##### **Patoladi kashaya**

It acts primarily through its diuretic, hepatoprotective, anti-inflammatory, and detoxifying properties. The decoction promotes diuresis, helping to remove excess fluid from the abdominal cavity, with herbs like *Patola* and *Patha* playing a key role in regulating water balance. It supports liver health through ingredients like *Katuki* and *Guduchi*, which enhance liver function and aid in detoxification, addressing the underlying hepatic dysfunctions often associated with ascites.

The anti-inflammatory properties of *Nimba* and *Vasa* help reduce peritoneal inflammation, alleviating discomfort and abdominal distension. Additionally, digestive herbs in the formulation, such as *Patha* and *Katuki*, improve gastrointestinal function, reducing bloating and supporting nutrient absorption. *Guduchi* and *Nimba* also enhance immunity, which is crucial in managing ascites linked to infections or systemic conditions. *Patoladi Kashaya* thus offers a holistic approach to the treatment of ascites, addressing both symptomatic relief and root causes.

##### **Punarnavasthaka kwatha**

*Punarnava* and *Gokshura* play a pivotal role in managing ascites by promoting diuresis, effectively reducing fluid retention in the abdominal cavity. *Punarnava*, along with *Guduchi*, supports liver regeneration and improves hepatic function, addressing ascites caused by liver cirrhosis or related disorders. Additionally, *Sunthi* and *Guduchi* provide anti-inflammatory benefits, alleviating abdominal

pain and discomfort. Digestive herbs such as *Pippali*, *Maricha*, and *Sunthi* enhance digestion, correct metabolic imbalances, and relieve symptoms like bloating and abdominal distension. *Amalaki* and *Haritaki* aid in detoxification by reducing toxin buildup, while *Guduchi* and *Amalaki* strengthen the immune system, which is particularly beneficial in ascites associated with infections or systemic illnesses. This holistic approach addresses both symptoms and underlying causes of ascites.

### **Chyavanprasha**

*Chyavanprasha*, a classical *Ayurvedic* formulation, is renowned for its rejuvenative, immunomodulatory, and detoxifying properties, which contribute to the holistic management of ascites. Although not a direct treatment for ascites, *Chyavanprasha* can play a supportive role by addressing associated symptoms and improving overall vitality.

The formulation contains herbs such as *Amalaki* (*Embllica officinalis*), a rich source of antioxidants, which helps combat oxidative stress and promotes liver health, thereby addressing one of the primary causes of ascites. Its detoxifying action assists in the elimination of toxins (*Ama*) from the body, reducing systemic inflammation and metabolic imbalances.

*Chyavanprasha* also enhances digestion and metabolism through its ingredients like *Pippali* (*Piper longum*) and *Sunthi* (*Zingiber officinale*), which help reduce bloating and improve nutrient absorption, alleviating common gastrointestinal symptoms associated with ascites. Additionally, its immunomodulatory herbs, such as *Guduchi* (*Tinospora cordifolia*), strengthen the immune system, making the body more resilient to infections that can exacerbate ascites.

By improving energy levels and overall health, *Chyavanprasha* supports recovery and complements other treatments for ascites, particularly when used as part of a comprehensive *Ayurvedic* management plan.

### **Bhumyamalaki Churna**

*Bhumyamalaki Churna*, prepared from the herb *Phyllanthus niruri*, is highly regarded in *Ayurveda* for its hepatoprotective, diuretic, and anti-inflammatory properties, making it an effective remedy for managing ascites.

This herbal powder primarily targets liver health, which is often compromised in ascites due to conditions like cirrhosis or hepatitis. *Bhumyamalaki* supports liver function by promoting the regeneration of liver cells and enhancing detoxification. Its ability to reduce elevated liver enzymes and prevent hepatic damage makes it valuable in addressing the root cause of fluid accumulation in the peritoneal cavity.

### **Shankha Vati**

*Shankh Vati* is a classical *Ayurvedic* formulation known for its efficacy in managing digestive disorders and metabolic imbalances, which play a significant role in the development and progression of ascites. While not a primary treatment for ascites, *Shankh Vati* serves as an effective adjuvant by addressing symptoms and improving overall digestive health.

This formulation helps regulate digestion and metabolism through its carminative and digestive-stimulant properties, reducing symptoms like bloating, abdominal distension, and indigestion, which are commonly associated with ascites. Ingredients such as *Shankha Bhasma* (conch shell ash) act as an antacid, alleviating hyperacidity and promoting gut health, which indirectly supports liver function and reduces fluid accumulation.

## **CONCLUSION**

This case study highlights the potential of *Ayurveda* in managing ascites by addressing the root cause, fluid accumulation, and hepatic dysfunction. The integrated approach using herbomineral drugs, *Panchakarma* therapies, and dietary modifications showed promising results, reducing abdominal girth, weight, and biochemical markers. Further clinical trials and pharmacological studies are warranted to establish *Ayurveda's* role in ascites management.

## **REFERENCES**

1. Pedersen JS, Bendtsen F, Møller S. (2015). Management of cirrhotic ascites. *Ther Adv Chronic Dis.* 6(3):124-137.
2. Kotihal M, Muttappa T, Vasantha B, Sandrima KS. (2017). Critical analysis of Jalodara (Ascites) – A review. *J Ayurveda Integr Med Sci.*2:150-153.
3. Acharya YT, editor. (2016). *Charaka Samhita of Charaka, Chikitsa Sthana*. Reprint ed. New Delhi: Chaukhambha Publications; p. 491-492.
4. Sharma RK, Dash B. *Charaka Samhita*. Vol. 2. Varanasi: Chaukhambha Sanskrit Series Office; 2007. p. 412-419.
5. Srivastava S. (2005). *Sharangadhar Samhita of Sharngadhara, Uttarkhanda*. Varanasi: Chaukhambha Orientalia; p. 345.
6. Dhanwantri Nighantu. Varanasi: Chaukhambha Orientalia; 2010. p. 153-158.

7. Pandey GS, editor. Bhavprakash Nighantu of Shri Bhavamisra, Guduchyadi Varga. Varanasi: Chaukhambha Bharati Academy; 2010. p. 393.
8. The Ayurvedic Formulary of India. Part 1. 2nd revised English ed. New Delhi: Ministry of Health and Family Welfare; 2003. p. 258.
9. Moore CM, Van Thiel DH. (2013). Cirrhotic ascites review: Pathophysiology, diagnosis and management. World J Hepatol. 5(5):251-263.
10. Chiejina M, Kudaravalli P, Samant H. (2025). Ascites. In: StatPearls [Internet]. Treasure Island (FL): StatPearls Publishing.
11. Jadhav DK.(2016). An Ayurvedic approach in the management of Jalodara (Ascites): A case study. Int J Ayurveda Res.1:90-91.
12. Shukla RB, Joshi NP, Thakar AB. (2017). A single-case study of management of Jalodara (ascites). AYU.;38(3-4):144-147.
13. Bhagiya SG, Shukla RB, Joshi NP, Thakar AB. (2017). A single-case study of management of Jalodara (ascites). AYU. 38:144-147.
14. Karhale N. (2021). Ayurvedic management of Jalodara (ascites) – A case study. Natl J Res Ayurved Sci. 9.
15. Gupta A.(2013). Jalodara: A comprehensive study. Anc Sci Life. 32:65-70.
16. Sen S, Pal D. (2015). Ayurvedic management of liver disorders. Asian J Pharm Res. 12:145-148.
17. Miller H, Thompson WD. (2015). Pathophysiology of portal hypertension and ascites. Liver Int. 30:109-114.
18. Pereira EPV, Tilburg MF, Tramontina Florean E, Florindo Guedes MI. (2019). Egg yolk antibodies (IgY) and their applications in human and veterinary health: A review. Int Immunopharmacol. 73:293-303.
19. Kumar P, Clark M. Clinical Medicine. 8th ed. Saunders; 2012. p. 347-349.
20. Williams R, Taylor A. (2015). Liver Disease Management. New York: Springer; p. 412-416.
21. Johnson J. (2017). Understanding cirrhosis-induced ascites. J Hepatol. 56:122-127.
22. Mishra P. (2018). Role of Ramayana's in Jalodara management. J Ayurveda. 4:24-30.
23. White G. (2016). Current advances in liver diseases. Int J Gastroenterol. 22:342-349.
24. Acharya S. (2020). Advances in Basti therapy. J Ayurveda Integr Med. 5:92-96.
25. Khatri A, Garg A, Agrawal SS. (2009). Evaluation of hepatoprotective activity of *Tephrosia purpurea* and *Tecomella undulata*. J Ethnopharmacol. 122:1-5.

**Copyright:** © 2025 Author. This is an open access article distributed under the Creative Commons Attribution License, which permits unrestricted use, distribution, and reproduction in any medium, provided the original work is properly cited.